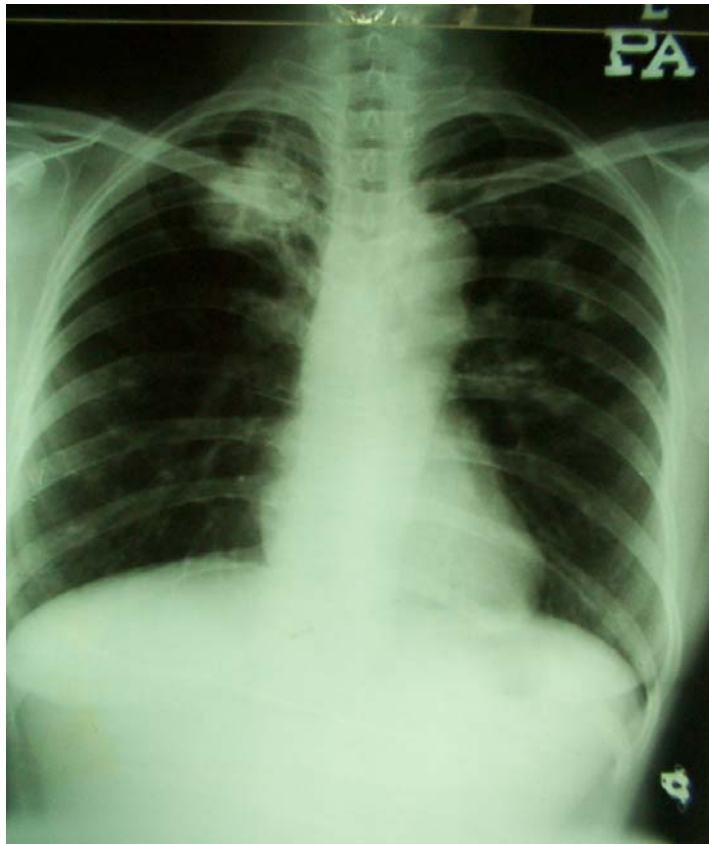
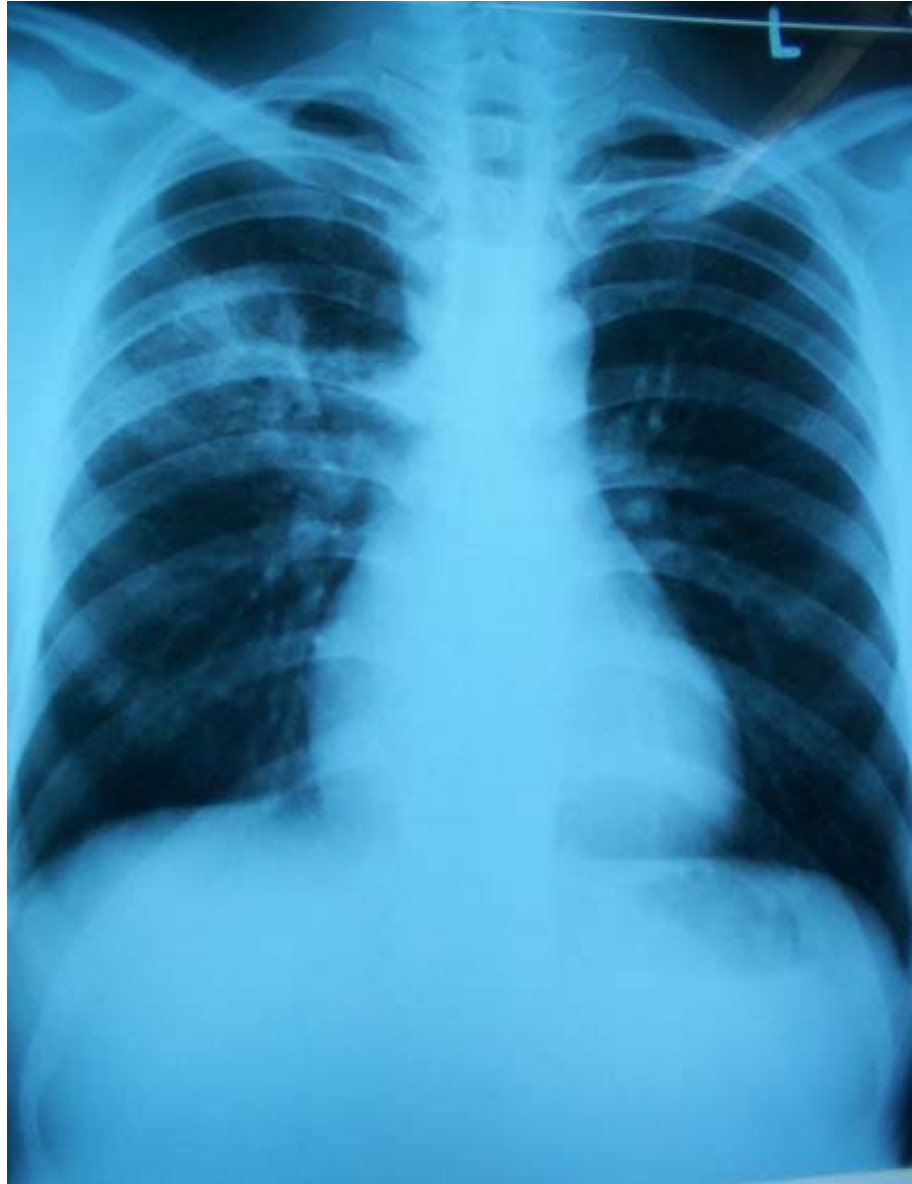


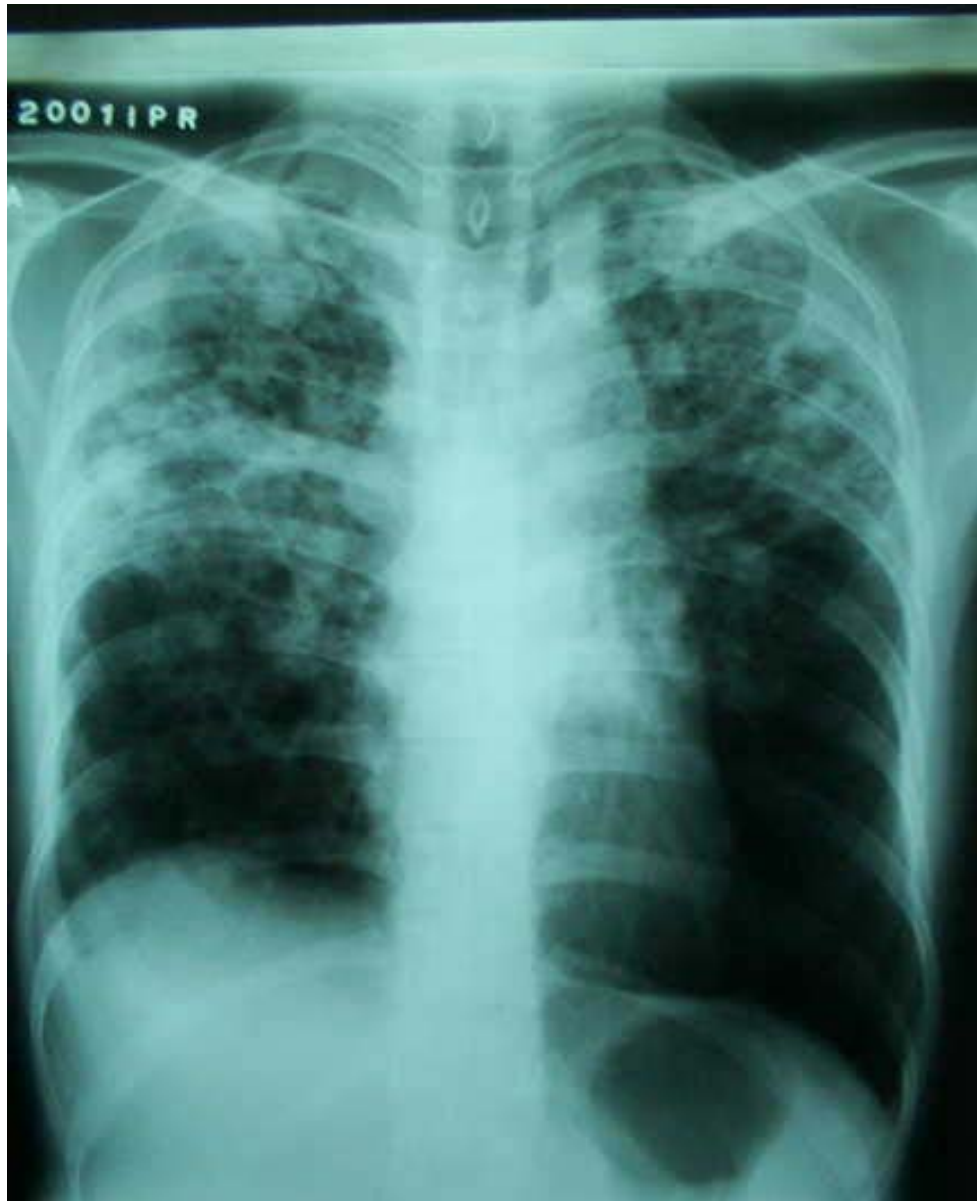
ASSESSMENT OF SEVERITY OF CHEST X-RAY IN PULMONARY TUBERCULOSIS



SEDERHANA (MINIMAL) – within the first rib **without cavitation**



TERUK (MODERATELY ADVANCED) – beyond first rib and unilateral



SANGAT TERUK (FAR ADVANCED) - bilateral